

# Comparison of rotary and reciprocal endodontics in shaping of root canal system

---

**Tomljanović, Magda; Božac, Elvis; Paljević, Ema; Vidas Hrstić, Jelena; Pezelj-Ribarić, Sonja; Brekalo Pršo, Ivana; Peršić Bukmir, Romana**

*Source / Izvornik:* **Journal of stomatology, 2022, 75, 141 - 146**

**Journal article, Published version**

**Rad u časopisu, Objavljena verzija rada (izdavačev PDF)**

<https://doi.org/10.5114/jos.2022.119079>

*Permanent link / Trajna poveznica:* <https://urn.nsk.hr/urn:nbn:hr:271:683936>

*Rights / Prava:* [In copyright](#)/[Zaštićeno autorskim pravom.](#)

*Download date / Datum preuzimanja:* **2024-12-28**

*Repository / Repozitorij:*

[Repository of the University of Rijeka, Faculty of Dental Medicine](#)



# COMPARISON OF ROTARY AND RECIPROCAL ENDODONTICS IN SHAPING OF ROOT CANAL SYSTEM

Magda Tomljanović<sup>1</sup>, Elvis Božac<sup>2</sup>, Ema Paljević<sup>2</sup>, Jelena Vidas Hrstić<sup>2</sup>, Sonja Pezelj-Ribarić<sup>3,4</sup>, Ivana Brekalo Pršo<sup>2,4</sup>, Romana Peršić Bukmir<sup>2</sup>

<sup>1</sup>Postgraduate student, Postgraduate doctoral study program Biomedicine, Medical Faculty, University of Rijeka, Rijeka, Croatia

<sup>2</sup>Department for Endodontics and Restorative Dentistry, Faculty of Dental Medicine, University of Rijeka, Croatia

<sup>3</sup>Department of Oral Medicine and Periodontology, Faculty of Dental Medicine, University of Rijeka, Rijeka, Croatia

<sup>4</sup>Department of Dental Medicine, Faculty of Dental Medicine and Health, J.J. Strossmayer University of Osijek, Osijek, Croatia

## ABSTRACT

**INTRODUCTION:** Inappropriate mechanical treatment of root canals can result in unfavorable outcome of root canal treatment.

**OBJECTIVES:** The aim of this study was to compare rotational and reciprocal instrumentation techniques by measuring the degree of dentin removal and preserving the original root canal anatomy.

**MATERIAL AND METHODS:** Twenty permanent mandibular molars extracted due to periodontal reasons were mechanically cleansed and randomly divided into two groups of ten teeth each. First group was instrumented with a rotational instrumentation technique, F360 system (Komet Dental, Lemgo, Germany), and second group was instrumented with Endo-Eze Genius reciprocating system (Ultradent Products, Utah, USA) according to manufacturers' protocols. Measurements of canal diameter and canal curvature straightening were obtained using standardized X-ray images taken before and after instrumentation at four levels of the root canal by utilizing computer software Adobe Photoshop CC 2020 (Adobe Systems Incorporated, San Jose, California, USA).

**RESULTS:** Rotational technique resulted in a statistically significant increase in the root canal diameter after instrumentation at all levels (all  $p < 0.05$ ). The reciprocating technique significantly increased the canal diameter at all levels (all  $p < 0.05$ ), except for the second level ( $p = 0.063$ ). Regarding the maintenance of root canal anatomy, both techniques led to canal alignment. When compared to reciprocal technique, rotational instruments caused significantly greater straightening of the curve at the third level ( $p = 0.017$ ).

**CONCLUSIONS:** Both instrumentation systems have similar degree of dentine removal; however, rotational technique is more prone to cause root canal straightening.

**KEY WORDS:** dental digital radiography, nitinol, root canal preparation.

J Stoma 2022; 75, 3: 141-146

DOI: <https://doi.org/10.5114/jos.2022.119079>

## INTRODUCTION

Endodontic treatment of teeth is a highly demanding procedure, involving mechanical instrumentation, chemical treatment, and three-dimensional filling of root

canals [1]. The success of treatment depends on each of these steps and Schilder's 1974 principles, which are divided into mechanical, biological, and clinical, and should be followed during treatment [2]. Mechanical instrumentation of the root canal removes pathologically altered or

**JOURNAL OF  
STOMATOLOGY**  
CZASOPISMO STOMATOLOGICZNE

OFFICIAL JOURNAL OF THE POLISH DENTAL ASSOCIATION | ORGAN POLSKIEGO TOWARZYSTWA STOMATOLOGICZNEGO



**ADDRESS FOR CORRESPONDENCE:** Prof. Romana Peršić Bukmir, Department for Endodontics and Restorative Dentistry, Faculty of Dental Medicine, University of Rijeka, 40 Kresimirova St., 51000 Rijeka, Croatia, e-mail: [rpersic@gmail.com](mailto:rpersic@gmail.com)

**RECEIVED:** 20.12.2021 • **ACCEPTED:** 16.05.2022 • **PUBLISHED:** 30.08.2022

infected necrotic tissue [2, 3]. Adequate instrumentation creates a tapered shape of the root canal with the widest part coronally. The apical foramen should remain in its' original position and should be kept as small as possible [2]. The goal of mechanical instrumentation is to preserve the integrity and original anatomy of the root canal space [2, 3]. Due to inadequate mechanical treatment of the canal, infected tissue may remain in the root canal, leading to therapy failure [4]. Also, mechanical instrumentation may cause protrusion of debris into the periapical area, which can lead to inflammation, abscess, prolonged healing time, and appearance of flare-up [5, 6].

Inappropriate mechanical treatment of root canals can result in mishaps, such as root canal perforation, ledging, or apical transportation (zipping), which can all result in unfavorable outcome of root canals' treatment [7, 8]. The apical transportation occurs due to over-preparation of outer aspect of the root canal curvature, which leads to a straightening of the root canal and teardrop-shaped apical part of canal [4, 9]. Given the increasing use of mechanically driven instrumentation techniques in clinical practice, the choice of rotational or reciprocal techniques depends on their advantages and disadvantages. Numerous studies compared parameters, which are important for successful endodontic treatment, including dentin cutting efficiency, maintenance of the root canal anatomy, cyclic and torsional fatigue, debris extrusion, and clinical efficiency [10, 11]. Compared to hand instruments, Ni-Ti engine-driven instruments remove a significantly larger volume of dentin during instrumentation. However, there are no unambiguous data on the degree of dentin removal regarding rotational and reciprocal instrumentation techniques. For example, Dietrich *et al.* [12] did not find statistically significant difference between rotational and reciprocal systems, while Bürklein *et al.* [13] demonstrated that reciprocal systems removed dentin more efficiently. In addition to the instrumentation technique itself, the obtained results can be influenced by different construction and cross-sections of instruments, the properties of Ni-Ti alloys due to their technological processing and the setting of endo unit [14].

As previously mentioned, preservation of the original root canal anatomy is an important prerequisite for successful endodontic treatment. Although the super-elasticity and shape memory effect of Ni-Ti instruments allow better adaptation to the root canal, no instrumentation technique can fully maintain the original root canal shape [3, 14]. The results of studies provided contradictory results; however, most of them suggested that reciprocal technique obtained better results in preservation of the original root canal anatomy [15, 16].

## OBJECTIVES

Considering the inconsistency of previous reports, the aim of the present research was to compare the rota-


tional and reciprocal instrumentation technique regarding the degree of dentin removal and the preservation of the original root canal anatomy. The null hypothesis tested was that there is no difference between rotational and reciprocal instrumentation technique regarding the degree of dentin removal and canal curvature straightening.

## MATERIAL AND METHODS

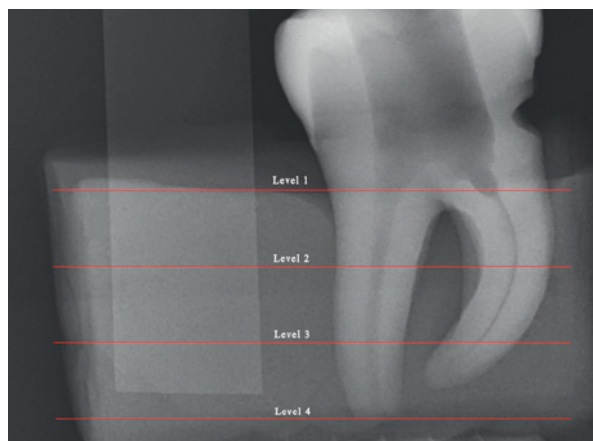
The research was performed at the Department of Endodontics and Restorative Dentistry, Faculty of Dental Medicine, University of Rijeka, Croatia. It was conducted in *in-vitro* conditions on twenty permanent mandibular molars extracted due to periodontal reasons. Each tooth had a fully developed roots, with no visible resorption and no root caries, and the teeth have not been previously endodontically treated. After extraction, their surfaces were mechanically cleansed, and they were stored in 0.1% thymol solution to prevent bacterial growth. To avoid superposition of root canals on radiologic images, instrumentation was performed on single-canal distal roots of mandibular molars.

Following the access cavity preparation, a pre-operative radiograph from bucco-lingual projection was taken. Radiographs were obtained utilizing X-ray unit (Trophy Elitys, Trophy Radiologie, Marne-la-Vallee, France) and intra-oral sensor (One, Owandy Radiology, Roslyn, NY, USA). Teeth with morphological abnormalities, obstructions, or multiple canals in distal root were excluded from the study. Cavity access set (Dentsply Sirona, Ballaigues, Switzerland) was used for access cavity preparation. A #10 size K-file was used to determine root canal length. Files with rubber stops were inserted into the canal until their tips became just visible through the apical foramen. To standardize root lengths in all teeth, they were shortened coronally to a length of 19 mm. By subtracting 1 mm from the adjusted length of the root, the working length in all teeth was set at 18 mm. Root canals were manually instrumented up to a size 20 K-file (Dentsply-Sirona, Ballaigues, Switzerland) to standardize apical diameter. The teeth were then randomly divided into two groups of ten teeth each. The first group was instrumented using a rotational instrumentation technique F360 (Kommet Dental, Lemgo, Germany). The second group was instrumented using Endo-Eze Genius (Ultradent Products, Utah, USA), a reciprocal system. Each rotary or reciprocal instrument was lubricated with Well-Prep (Vericom Co., Ltd.; Anyang, Korea). After the use of each instrument, the canal was rinsed with a 3 ml of 3% NaOCl solution. Apical patency was maintained with a size 10 K-file.

F360 system was applied according to the manufacturer's protocol. Coronal flaring of the root canal was performed using Opener instrument (#30/.10). The root canal was instrumented to the working length, with a red mark instrument (#25/.04) and a green mark in-



**FIGURE 1.** X-ray tube holder that ensures equal tube position in relation to the tooth and to the sensor



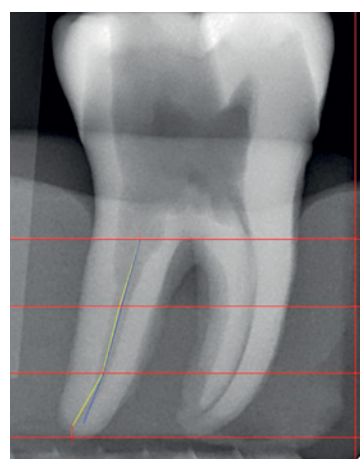
**FIGURE 2.** X-ray from bucco-lingual projection showing the distal root canal divided into four equal levels

strument (#35/.04). Instrumentation was performed using Endo-Eze Genius motor, with settings according to the manufacturer's recommendations for F360 system (300 r.p.m.; torque 1.8 Ncm).

Endo-Eze Genius instruments were applied according to the manufacturer's protocol using Endo-Eze Genius motor at reciprocal motion settings (350 r.p.m.; CW: 90°; CCW: 30°). Orifice shaper (#30/.08) was applied for coronal flaring. Instrumentation began with a red mark instrument (#25/.04) and ended with a green mark instrument (#35/.04), which was used with a rotary instrumentation setting (300 r.p.m., torque 0.5 Ncm) to smooth the root canal walls.

After finishing the instrumentation, another radiograph from bucco-lingual projection was taken. To ensure an equal radiologic tooth image with respect to the distance and angle, each tooth was immersed in silicone (Optosil P Plus®; Kulzer GmbH, Germany) to obtain an individual mold. A 6 mm wide metal strip was placed next to the teeth for the purpose of image calibration. An X-ray tube holder was created to ensure an equal distance between the X-ray tube and the individual mold (10 cm), and a groove on the holder provided an equal shooting angle (Figure 1). In this way, the tooth was in the same position before and after the instrumentation, which enabled precise measurement.

X-rays images before and after instrumentation were converted to .png images. Each image was calibrated so that the measurement could be expressed in millimeters. The measurement was performed in computer software Adobe Photoshop CC 2020 (Adobe Systems Incorporated, San Jose, California, USA). The first parameter, degree of dentin removal, was measured in a way that the root canal of each tooth was divided into coronal, middle, and apical third, resulting in four equal levels (Figure 2). At each of these levels, diameter before and after instrumentation was measured. Data on the preservation of original root canal anatomy were obtained by determining at



**FIGURE 3.** X-ray showing superposition of the curves before and after instrumentation

each level a point representing half the diameter, and by merging these points, a curve was obtained. By superimposing the images before and after the instrumentation, distance between the curves was measured at each of the four levels, thus obtaining data on the root canal curvature straightening between rotational and reciprocal instrumentation techniques (Figure 3).

## STATISTICAL ANALYSIS

Raw data were entered into MS Excel database (Microsoft Corporation, Redmond, USA), followed by statistical analysis using computer software Statistica for Windows, release 13.5 (StatSoft, Inc.; Tulsa, OK, USA). All results were interpreted at a level of statistical significance  $p \leq 0.05$ . Measures of diameters before and after the instrumentation were expressed as mean and standard deviation. *T*-test for dependent samples was applied to determine the differences of root canal diameters before and after the instrumentation with rotary or reciproc-

**TABLE 1.** Diameter analysis before and after instrumentation using rotational technique

Level	Before instrumentation; mean $\pm$ standard deviation (mm)	After instrumentation; mean $\pm$ standard deviation (mm)	<i>p</i> -value
1	0.764 $\pm$ 0.328	0.879 $\pm$ 0.290	0.027*
2	0.399 $\pm$ 0.087	0.467 $\pm$ 0.093	0.045*
3	0.174 $\pm$ 0.113	0.359 $\pm$ 0.055	< 0.001*
4	0.174 $\pm$ 0.113	0.307 $\pm$ 0.092	0.001*

\*Statistically significant

**TABLE 2.** Diameter analysis before and after instrumentation using reciprocal technique

Level	Before instrumentation; mean $\pm$ standard deviation (mm)	After instrumentation; mean $\pm$ standard deviation (mm)	<i>p</i> -value
1	0.801 $\pm$ 0.260	0.907 $\pm$ 0.196	< 0.001*
2	0.545 $\pm$ 0.174	0.615 $\pm$ 0.155	0.063
3	0.359 $\pm$ 0.083	0.493 $\pm$ 0.105	< 0.001*
4	0.238 $\pm$ 0.106	0.359 $\pm$ 0.091	< 0.001*

\*Statistically significant

**TABLE 3.** Diameter difference before and after instrumentation between rotary and reciprocal techniques

Level	Rotational technique; mean $\pm$ standard deviation (mm)	Reciprocal technique; mean $\pm$ standard deviation (mm)	<i>p</i> -value
1	0.115 $\pm$ 0.138	0.106 $\pm$ 0.100	0.870
2	0.068 $\pm$ 0.092	0.070 $\pm$ 0.105	0.964
3	0.185 $\pm$ 0.090	0.134 $\pm$ 0.077	0.194
4	0.133 $\pm$ 0.088	0.121 $\pm$ 0.063	0.729

\*Statistically significant

**TABLE 4.** Difference of superimposed curves between rotational and reciprocal instrumentation techniques

Level	Rotational technique; mean $\pm$ standard deviation (mm)	Reciprocal technique; mean $\pm$ standard deviation (mm)	<i>p</i> -value
1	0.122 $\pm$ 0.140	0.130 $\pm$ 0.136	0.899
2	0.120 $\pm$ 0.080	0.086 $\pm$ 0.056	0.284
3	0.112 $\pm$ 0.053	0.050 $\pm$ 0.053	0.017*
4	0.101 $\pm$ 0.075	0.087 $\pm$ 0.057	0.644

\*Statistically significant

cal technique, respectively. To analyze the differences in root canal diameters between the two techniques, *t*-test for independent samples was utilized.

To explore the difference in the straightening of superimposed canal curves between rotational and reciprocal techniques, *t*-test for independent samples was used.

## RESULTS

The use of rotational instrumentation significantly increased the diameter of the root canals at all four levels (all  $p < 0.05$ ; Table 1). Regarding the reciprocal instrumentation technique, the instrumentation significantly increased canal diameter at the first ( $p < 0.001$ ), third ( $p < 0.001$ ), and fourth level ( $p < 0.001$ ), while at the second level, there was no statistically significant increase in the root canal diameter ( $p = 0.063$ ; Table 2). No statistically significant difference in diameter before and after root canal instrumentation was found between the rotational and reciprocal instrumentation techniques at any level (Table 3). Comparison of the root canal curvature straightening between two techniques revealed a significant difference at the third level. Rotational technique caused significantly larger straightening of the curve at the third level ( $p = 0.017$ ). No statistically significant difference was found at other levels (Table 4).

## DISCUSSION

The results of the study showed that both instrumentation techniques led to a significant increase in the diameter of the root canals, and no statistically significant difference was found between them at either level. Both techniques are equally effective in dentin removal. These results are congruent with findings of a several surveys that compared rotary and reciprocal systems [12, 17, 18]. The amount of dentin to be removed in the middle and apical third should be sufficient to allow chemical irrigants to penetrate the apical third, but enough amount of dentinal wall should also remain to prevent root fracture. A research by Brkanic *et al.* [19] compared five rotary (ProTaper, GT, ProFile, K3, and FlexMaster), two reciprocal systems (ProTaper and GT), and two hand instrumentation techniques. The results showed that there were no statistically significant differences between these groups of instruments, and that all systems provided adequate dentin removal. Compared to hand instruments, Ni-Ti engine-driven instruments removed significantly higher dentin volume due to the use of greater force during instrumentation [19]. Using greater force may lead to a formation of cracks that can extend to the outer root surface [4]. The results may also be affected by the use of a paste-like lubricant during instrumentation. Although manufacturers recommend its' use because of stress reduction on the instruments, certain research has shown that they can



reduce dentin cutting efficiency [20, 21]. In addition to the degree of dentin removal, the present study compared the preservation of original anatomy between the two instrumentation techniques. It should be noted that the second group was not fully shaped with the reciprocal movement. Finishing Endo-Eze Genius file (#35/.04) was applied in full rotation as instructed by the manufacturer, which could affect the results. The results show that both instrumentation techniques led to root canal straightening, with no statistically significant difference at three of the four levels. A statistically significant difference was found at the third level, where a significantly larger curve deviation occurred using the rotational instrumentation technique. Similar results were found by two large studies [15, 16]. A study of Berutti *et al.* [15] comparing WaveOne (Dentsply Maillefer, Ballaigues, Switzerland) and ProTaper Universal systems (Dentsply Maillefer, Ballaigues, Switzerland) proved that instrumentation with the reciprocal WaveOne single-file technique allows better preservation of the original root anatomy. Likewise, Yoo *et al.* [16] compared four systems: Reciproc (VDW, Munich, Germany), WaveOne (Dentsply Maillefer, Ballaigues, Switzerland), ProTaper Universal (Dentsply Maillefer, Ballaigues, Switzerland), and ProFile (Maillefer Instruments SA, Ballaigues, Switzerland) also showing that reciprocal techniques (Reciproc and WaveOne) ensured better preservation of the root canal anatomy. On the other hand, a study comparing MTwo (Dentsply Maillefer or VDW, Ballaigues, Switzerland) and Reciproc instrumentation systems (VDW, Munich, Germany) [22] proved that Reciproc provided greater apical transportation. Similar results were shown by another study [23], in which Reciproc system also showed higher apical transportation compared with BioRace (FKG Dentaire, La Chaux de Fonds, Switzerland) system. Capar *et al.* [24] compared six systems (OneShape, ProTaper Universal, ProTaper Next X2, Reciproc, Twisted File Adaptive, and SM2 WaveOne); however, the study did not demonstrate a statistically significant difference in apical transport, canal curvature and centering ability. A statistically significant difference was found for Reciproc system since it demonstrated higher effectiveness in dentin removal.

Due to a tendency of instruments straightening, the apical transportation of the root canal occurs as a result. Further instrumentation forms the apical part of the root canal in the teardrop-shaped form, which can lead to root perforation. Prognosis of the root perforation depend on the ability to re-find the original canal, ratio of un-instrumented and unfilled part of the canal, and initial diagnosis. The consequence of transportation is insufficiently cleaned root canal, which is weakened and has an increased possibility of root fracture. Accordingly, the preservation of the original anatomy is of considerable importance [9].

Since the results are influenced not only by the instrumentation technique, but also by other parameters, such as instrument design, cross section, endo unit set-

tings, and properties of Ni-Ti alloys used, these parameters should be compared in further research. Studies have shown that the experience of operator does not affect the results [25, 26].

The current experimental set-up allowed X-ray imaging of the teeth before and after instrumentation in exactly the same position, ensuring the reproducibility of the results. It is newly proposed set-up by the researchers since the method has not been described in detail in previous research. However, the two-dimensional nature of images did not allow complete investigation of the root canal anatomy. Therefore, to obtain more reliable conclusions, three-dimensional imaging technique should be used.

Regarding the method of measuring the angles of root canals according to a two-dimensional X-ray, there are several methods applied in previous research. This study used a modification of a method described by Berbert and Nishiyama [27].

Regarding the degree of dentin removal, the null hypothesis for this research was accepted. However, the present study demonstrated that rotational technique is more prone to cause root canal straightening.

## CONCLUSIONS

Within the limitations of the present study, the conclusion is that the two instrumentation systems have similar degree of dentine removal; however, the rotational technique is more prone to cause root canal straightening.

## CONFLICT OF INTEREST

The authors declare no potential conflicts of interest with respect to the research, authorship, and/or publication of this article.

## References

1. Dioguardi M, Troiano G, Laino L, et al. ProTaper and WaveOne systems three-dimensional comparison of device parameters after the shaping technique. A micro-CT study on simulated root canals. *Int J Clin Exp Med* 2015; 8: 17830-17834.
2. Schilder H. Cleaning and shaping the root canal. *Dent Clin North Am* 1974; 18: 269-296.
3. Hülsmann M, Peters OA, Dummer PMH. Mechanical preparation of root canals: shaping goals, techniques and means. *Endod Topics* 2005; 1: 30-76.
4. Walton RE, Torabinejad. *Principle and Practice of Endodontics*. 3<sup>rd</sup> ed. Saunders; 2002.
5. Sowmya HK, Subhash TS, Goel BR, Nandini TN, Bhandi SH. Quantitative assessment of apical debris extrusion and intracanal debris in the apical third, using hand instrumentation and three rotary instrumentation systems. *J Clin Diagn Res* 2014; 8: 206-210.
6. Siqueira JF. Microbial causes of endodontic flare-ups. *Int Endod J* 2003; 36: 453-463.
7. Menezes Aguiar C, Gomes Faria C, Cruz Camara A, Frazao M. Comparative evaluation of the Twisted File™ and Revo-S® rotary

- systems using cone beam computed tomography. *Acta Stomatol Croat* 2012; 46: 222-229.
8. Gergi R, Arbab-Chirani R, Osta N, Naaman A. Micro-computed tomographic evaluation of canal transportation instrumented by different kinematics rotary nickel-titanium instruments. *J Endod* 2014; 40: 1223-1227.
  9. Schäfer E, Dammaschke T. Development and sequelae of canal transportation. *Endodontic Topics* 2006; 15: 75-90.
  10. K Sahu G, Consul S, Nandakishore KJ, Shubhashini N, Geeta IB, Idris MD. Rotary endodontics or reciprocating endodontics: which is new and which is true? *J Health Sci Res* 2016; 7: 51-57.
  11. Laurindo FV, Poli de Figueiredo JA. Reciprocating versus rotary instruments: a review. *Revista Odonto Ciencia* 2016; 31: 135.
  12. Dietrich M, Kirkpatrick T, Yaccino J. In vitro canal and isthmus debris removal of the Self-Adjusting File, K3, and WaveOne files in the mesial root of human mandibular molars. *J Endod* 2012;38:1140-1144.
  13. Bürklein S, Hinschitzka K, Dammaschke T, Schäfer E. Shaping ability and cleaning effectiveness of two single-file systems in severely curved root canals of extracted teeth: Reciproc and WaveOne versus Mtwo and ProTaper. *Int Endod J* 2012; 45: 449-461.
  14. Zupanc J, Vahdat-Pajouh N, Schäfer E. New thermomechanically treated NiTi Alloys – a review. *Int Endod J* 2018; 51: 1088-1103.
  15. Berutti E, Chianddussi G, Paolino DV, Scotti N, Cantatore G, Castellucci A. Canal shaping with WaveOne primary reciprocating files and ProTaper system. A comparative study. *J Endod* 2012; 38: 505-509.
  16. Yoo Y, Cho Y. A comparison of the shaping ability of reciprocating Ni-Ti instruments in simulated curved canals. *Restor Dent Endod* 2012; 37: 220-227.
  17. Franco V, Fabiani C, Taschieri S, Malentacca A, Bortolin M, Fabbro MD. Investigation on the shaping ability of nickel-titanium files when used with a reciprocating motion. *J Endod* 2011; 37: 1398-1401.
  18. Wei Z, Cui Z, Yan P, Jiang H. A comparison of the shaping ability of three nickel-titanium rotary instruments: a micro-computed tomography study via a contrast radiopaque technique in vitro. *BMC Oral Health* 2017; 17: 39.
  19. Brkanic T, Stojsin I, Zivkovic S, Vukoje K. Canal wall thickness after preparation with NiTi rotary files. *Microsc Res Tech* 2012; 75: 253-257.
  20. Peters OA, Boessler C, Zehnder M. Effect of liquid and paste-type lubricants on torque values during simulated rotary root canal instrumentation. *Int Endod J* 2005; 38: 223-229.
  21. Chen G, Chang YC. Effects of liquid- and paste-type EDTA on smear-layer removal during rotary root-canal instrumentation. *J Dent Sci* 2011; 6: 41-47.
  22. Hwang YH, Bae KS, Baek SH, et al. Shaping ability of the conventional nickel-titanium and reciprocating nickel-titanium file systems: a comparative study using micro-computed tomography. *J Endod* 2014; 40: 1186-1189.
  23. Nabavizadeh M, Abbaszadegan A, Khojastepour L, Amirhosseini M, Kiani E. A comparison of apical transportation in severely curved canals induced by reciproc and biorace systems. *Iran Endod J* 2014; 9: 117-122.
  24. Capar ID, Ertas H, Ok E, Arslan H, Ertas ET. Comparative study of different novel nickel-titanium rotary systems for root canal preparation in severely curved root canals. *J Endod* 2014; 40: 852-856.
  25. Goldberg M, Dahan S, Machtou P. Centering ability and influence of experience when using WaveOne single-file technique in simulated canals. *Int J Dent* 2012; 2012: 206321.
  26. Muñoz E, Forner L, Llana C. Influence of operator's experience on root canal shaping ability with a rotary nickel-titanium single-file reciprocating motion system. *J Endod* 2014; 40: 547-550.
  27. Hartmann RC, Fensterseifer M, Peters OA, de Figueiredo JAP, Gomes MS, Rossi-Fedele G. Methods for measurement of root canal curvature: a systematic and critical review. *Int Endod J* 2019; 52: 169-180.