

Retention using braided bonded wires: a 2-year follow-up of the dentition and oral hygiene with predictors of relapse

Ugrin, Silvija Kanižaj; Dzipunova, Biljana; Špalj, Stjepan

Source / Izvornik: **Australasian Orthodontic Journal**, 2023, 39, 113 - 122

Journal article, Published version

Rad u časopisu, Objavljena verzija rada (izdavačev PDF)

<https://doi.org/10.2478/aoj-2023-0030>

Permanent link / Trajna poveznica: <https://um.nsk.hr/um:nbn:hr:271:276906>

Rights / Prava: [Attribution 4.0 International](#) / [Imenovanje 4.0 međunarodna](#)

Download date / Datum preuzimanja: **2024-05-17**

Repository / Repozitorij:

[Repository of the University of Rijeka, Faculty of Dental Medicine](#)



Retention using braided bonded wires: a 2-year follow-up of the dentition and oral hygiene with predictors of relapse

Silvija Kanizaj Ugrin,^{*} Biljana Dzipunova[†] and Stjepan Spalj^{‡§}

Private practice, Orthonova Dental Clinic Zagreb, Croatia^{*}

Associate Professor, Ss. Cyril and Methodius University of Skopje, Faculty of Dentistry, Skopje, North Macedonia[†]

Professor, University of Rijeka, Faculty of Dental Medicine, Rijeka, Croatia[‡]

Professor, J.J. Strossmayer University of Osijek, Faculty of Dental Medicine and Health, Osijek, Croatia[§]

Objective: To assess gingival health and predictors of relapse related to braided-wire bonded retainers after the active phase of comprehensive orthodontic treatment.

Materials and methods: Fifty-one subjects were recruited in a prospective study of whom 42 were available for analysis after 2 years of retention (pre-therapeutic ages 11–18 years; 66% female). A rectangular wire retainer (0.027 × 0.011") was bonded to the mandibular incisors. Little's index of incisor irregularity; intercanine width; the accumulation of biofilm, calculus and gingivitis; and the incidence of retainer detachment, were recorded. Subjects were examined before orthodontic therapy, upon therapy completion, and after 2 years of retention.

Results: The incidence of retainer detachment over the 2 years was 27%. The post-treatment incidence of irregularity was 17%, and intercanine width reduction was 24%. Calculus accumulation increased significantly during retention ($p < 0.001$) but not the extent of gingivitis. A multiple logistic regression demonstrated that an increase of mandibular intercanine width by ≥ 3 mm correspondingly increased the odds of relapse 14.3 times (95% confidence interval [CI], 1.1–196.1; $p = 0.046$). Patients presenting with retainer failure were 10 times (95% CI 1.6–62.8; $p = 0.014$) more likely to experience relapse. Subjects who experienced relapse had retainer failure earlier than those without relapse (19 vs. 23 months; $p = 0.003$). The occurrence of relapse was not related to a treatment change in incisor irregularity, the duration of treatment, the age of the patient, gender nor to a change of intercanine width during retention.

Conclusion: Post-treatment changes in the mandibular arch incorporating bonded retainers were not large, but were common. An increase in mandibular incisor irregularity during retention is mostly related to treatment-induced intercanine width expansion. The bonded retainer often detached and increased calculus accumulation.

(Aust Orthod J 2023; 39: 113 - 122. DOI: 10.2478/aoj-2023-0030)

Received for publication: February, 2023

accepted: October, 2023.

Silvija Kanizaj Ugrin: kanizaj.ugrin@gmail.com; Biljana Dzipunova: bdzipunova@stomfak.ukim.edu.mk;
Stjepan Spalj: stjepan.spalj@fdmri.uniri.hr

Introduction

Retention is a challenging component of orthodontic treatment which aims to maintain the final occlusal outcome and preserve the teeth in corrected alignment following fixed appliance removal. Several gingival, periodontal, occlusal and growth-related

factors influence the tendency of the teeth to move back towards their original position, which makes the prevention of relapse after orthodontic treatment, demanding.^{1–4}

Orthodontists have long been aware of the necessity for retention⁵ and over the years, opinions on the

factors that have the greatest influence on stability have changed. It was believed that the most important factor for the preservation of a treatment result was the occlusion, rather than the apical base, canine and molar relationships or incisor inclination.^{6–8} The retention phase is currently considered crucial for stability and retainers help achieve a balance between the occlusal forces produced by the masticatory muscles and the forces produced by the tongue, cheeks and lips. As peri-oral forces are constantly active, orthodontists often advise lifelong retention.⁹ For patient acceptance, retainers should be as comfortable as possible and have minimal effects on orofacial function, related to speech and chewing, oral health and the maintenance of oral hygiene.

Currently, fixed retainers are accepted for lifelong retention strategies and are frequently used because of their many advantages, related to effectiveness, low visibility and little need for patient co-operation.¹⁰ In addition, they may be combined with thermoplastic clear removable retainers. The bonded orthodontic retainers, constructed from multi-strand or steel wires of different sizes and shapes, allow the physiologic movement of teeth, so that alignment can be maintained long-term.¹¹ However, the disadvantages of these retainers are their need for precise bonding techniques, and the fragility and propensity to cause periodontal problems by hampering oral hygiene.¹¹ Moreover, the placement method is time consuming and technique sensitive.¹² In addition, fixed retainers experience a high incidence of breakage and debonding (5–37% in the mandible and 23–58% in the maxilla).¹³

Five generations of wires used in the manufacturing of fixed retainers have been introduced.¹⁴ Originally, plain round or rectangular orthodontic wires were used until Zachrisson suggested the use of multi-stranded wires.¹⁵ He described his experience with 5-strand wires of 0.0215 inch diameter, which produced better results based on failure rates found in a review of finished cases.¹⁶ In recent years, glass fibre reinforced composite orthodontic retainers have emerged as an alternative to stainless steel wires.^{17,18} In addition, bonded retainers manufactured using computer-aided design/computer-aided manufacturing technology have been introduced.^{19,20}

Long-term stability of mandibular anterior alignment is seldom expected, and according to longitudinal studies, a high percentage of people will experience a

small to moderate increase in incisor irregularity.^{21,22} Furthermore, parameters such as the proclination of the incisors, the initial crowding, the pattern of rotational growth of the face, the sagittal relationship of the jaws, gender or age, have not been identified as predictors of stability.^{21,22}

Therefore, the objective of the present research was to assess changes in the dentition and gingival health during retention using a bonded retainer after the active phase of orthodontic treatment and the relationship of relapse with the pre-therapeutic condition, treatment duration, age, gender and retainer detachment. It was hypothesised that post-treatment changes were likely related to the extent of treatment change and treatment duration. A deterioration of oral hygiene and an increase in the accumulation of biofilm, calculus and gingivitis are expected during retention, particularly in males rather than in females. Furthermore, an increase in intercanine width is expected to be the principal predictor of relapse.

Materials and methods

The study was approved by the Ethics Committee of the Faculty of Dental Medicine Rijeka (No: 2170-57-006-01-22-1). Patients provided written informed consent.

A total of 51 subjects were recruited for the present prospective single-centre observational study using a convenience sampling. The inclusion criteria were patients in the permanent dentition, 11 to 18 years of age, without hypodontia nor tooth loss, presenting with a dental sagittal Class I or mild Class II or III relationship, and with a healthy periodontium of the mandibular anterior teeth. Cases planned for hyrax expander treatment, extractions, mini-implants or orthognathic surgery were not included in the study. The treatment was performed using a labial multibracket fixed appliance of MBT prescription 0.022" slot incorporating an ovoid arch form without individualisation, and following a sequence of 0.012" NiTi, 0.018" NiTi, 0.018 × 0.025" NiTi, leading to 0.019 × 0.025" stainless steel wires. Manual interproximal enamel reduction was undertaken. A 0.027 × 0.011" rectangular wire retainer (Bond-A- Braid Retention Wire, Reliance Orthodontic Products, Itasca IL, USA) was bonded to the mandibular teeth from one canine to the

contralateral canine, on the lingual aspect of each tooth, following the active phase of comprehensive orthodontic treatment. The retainers were adapted on plaster casts and bonded after enamel etching using adhesive and flowable composite (Multilink,

3M, St. Paul, USA and Filtek, Ivoclar Vivadent, Shaan, Lichtenstein). All retainers were made by the same operator (SKU). A vacuum-formed clear retainer (1 mm foil thickness) was manufactured for the maxillary teeth. All patients received the

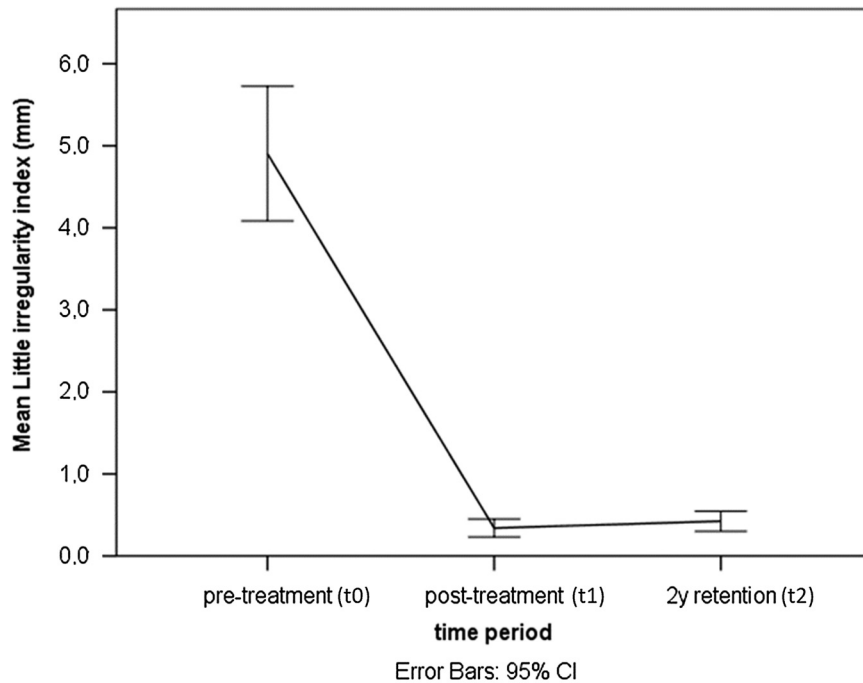


Figure 1. Changes in mandibular incisor irregularity.

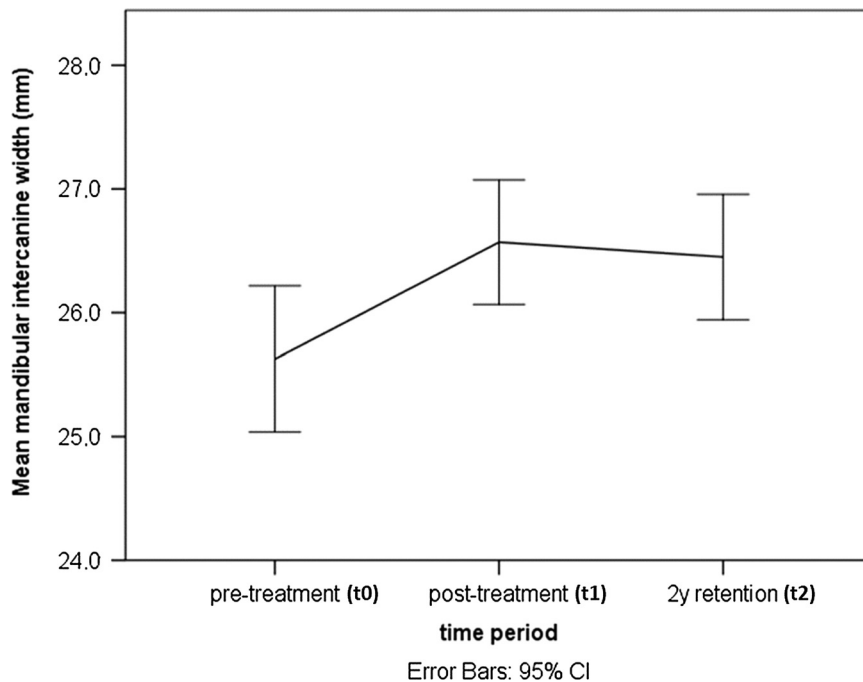


Figure 2. Changes in mandibular intercanine width.

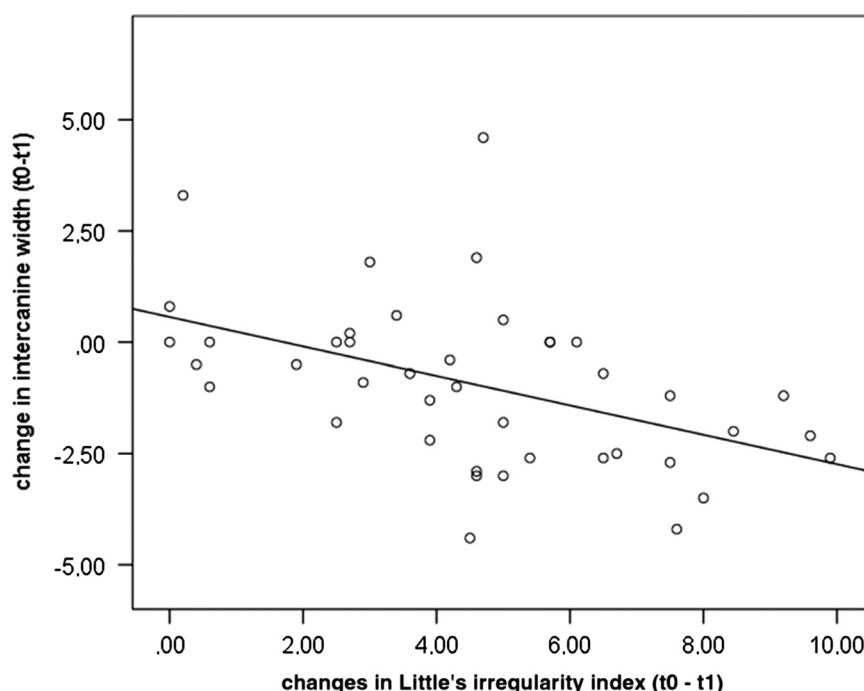


Figure 3. Relationship among changes in dentition induced by treatment.

same oral hygiene instructions. Interdental brushes were not recommended so that they would not be implicated in breakage and debonding. Brushing of the teeth and flossing the interdental spaces was recommended. The use of dental floss and a floss threader was advised for cleaning the spaces under the fixed retainers. Regular check-ups were arranged 3, 6, 12 and 24 months after retainer bonding, but patients were instructed to report to the office and outside regular review appointments as soon as retainer failure was noticed, following which the affected wire was rebonded or replaced. The drop-out rate after 2 years of retention was 20%, and so the sample for analysis consisted of 42 subjects whose pre-therapeutic ages were between 11 and 18 years (median 14 years; interquartile range 13–16 years; 66% women). The age at debonding was 12 to 21 years (median 16 years; interquartile range 15–18 years). Little's index of irregularity of the incisors and intercanine width were assessed on plaster casts using a sliding calliper (Digital caliper, Burg-Wächter KG, Wetter, Germany).²³ The accumulation of biofilm, calculus and gingivitis, and the incidence of retainer detachment were recorded. All measurements were conducted on the mandibular dentition.^{24–26}

Periodontal indices were assessed after 6 months and 2 years of retention on the mandibular six anterior

teeth (canine to canine) in 4 places (mesial, distal, buccal and lingual) using a periodontal probe (CP -15 University of North Carolina, Hu-Friedy Mfg. Co., Chicago, IL, USA). Values per subject were expressed as the proportion of affected measurement sites (0–100%). The dentition of the subjects was examined before orthodontic therapy, upon completion, and after 2 years of retention. Oral hygiene, calculus and gingivitis were assessed after 6 months and 2 years. The evaluator was the same person who treated the patients.

The Fischer test, Student's *t* test, analysis of variance for repeated measurements with Sidak post- hoc test, Pearson correlation, Kaplan–Meier analysis with a log-rank test, linear and logistic regression were applied for statistical analysis using commercial software (IBM SPSS version 22, IBM, Armonk, USA).

Results

The overall treatment duration ranged between 13 and 45 months (median 20 months; interquartile range 17–24 months; average 22 ± 1 months). At the start, Little's irregularity index of the mandibular incisors was in the range of 0.4 to 10.2 mm (median 4.9 mm; interquartile range 3–6.5 mm;

average 4.9 ± 2.6 mm). The mandibular intercanine width at the start was 20.4 to 29 mm (median 25.6 mm; interquartile range 24.3–27.1 mm; mean 25.6 ± 1.9 mm).

Orthodontic treatment significantly corrected the incisor irregularity to a level of 0.4 to 9.9 mm (mean 4.6 ± 2.7 mm) and changed the intercanine width between -4.4 and 4.6 mm (mean 0.9 ± 1.9 mm; $p < 0.05$; Figures 1 and 2).

There were no differences between the genders. The treatment change in intercanine width was linearly inversely correlated with the therapeutic change in Little's index ($r = -0.472$; $p = 0.002$; Figure 3). As the intercanine width increased, the irregularity of the incisors decreased. Linear regression revealed that for every 1 mm increase in intercanine width, incisor irregularity improved by 0.7 mm.

The incidence of retainer detachment over the 2-year retention period amounted to 27% of the cases (on average 0.6 ± 0.8 times per person; range 0–3 times), equally in both genders. There was a small but statistically significant increase in incisor irregularity during retention, while a decrease in intercanine width was not significant. The post-treatment incidence of irregularity was 17% (irregularity in the range of 0–0.8 mm, mean 0.1 ± 0.2 mm)

without differences between the genders. Post-treatment changes in mandibular intercanine width ranged between -0.7 and 1.5 mm, and the incidence of mandibular intercanine width reduction was 24% (mean severity 0.1 ± 0.4 mm). There were no differences between the genders. The post-treatment change in incisor irregularity correlated linearly and inversely with the post-treatment change in intercanine width ($r = -0.668$; $p < 0.001$; Figure 4). As the intercanine width decreased, the irregularity of the incisors increased. According to the linear regression, for every 1 mm of reduction of intercanine width, the irregularity increased by 0.4 mm. Post-treatment changes in mandibular incisor alignment were related to the amount of treatment change in intercanine width ($r = 0.443$; $p = 0.003$), but not in the resolution of incisor irregularity by treatment or treatment duration. The change in Little's index was significant between the time periods ($p < 0.001$) and the change in intercanine width ($p = 0.003$). The increase in Little's index in retention was also significant, while the decrease in intercanine width during retention was not significant.

Calculus accumulation increased significantly during retention ($p < 0.001$), but not biofilm accumulation and gingivitis extent (Figure 5).

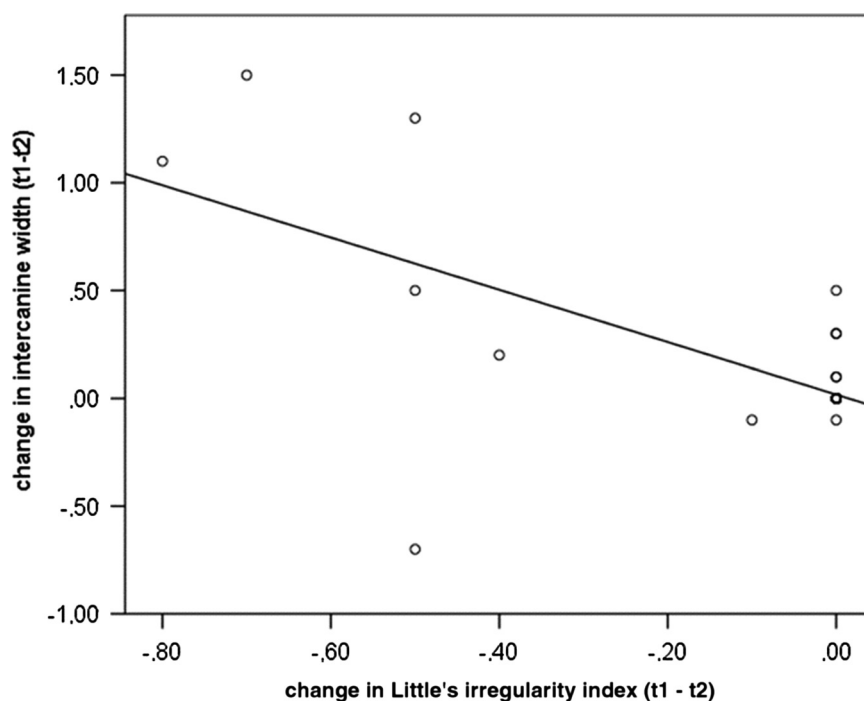


Figure 4. Relationship between the changes in the dentition during the retention period.

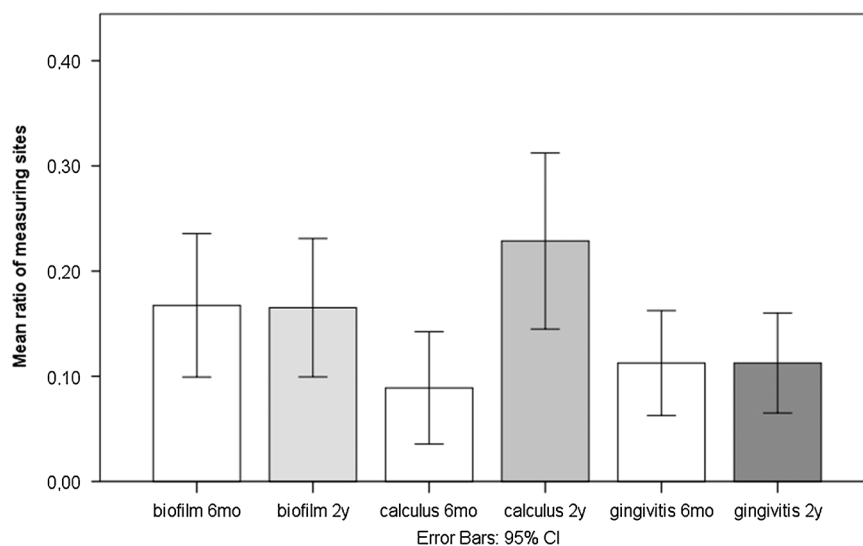


Figure 5. Changes in dental biofilm, calculus accumulation and gingivitis extent.

The Kaplan–Meier analysis with a log-rank test demonstrated that, on average, failure was earlier in subjects who experienced some relapse (19 months; 95% confidence interval [CI] 15.8–22.2) than in those who did not experience relapse (23.2 months; 95% CI 21.9–24.6; $p = 0.003$; Figure 6). Univariate analyses determined that the occurrence of relapse (dichotomised 0 = no change in Little's index in retention period; 1 = some change) was related to treatment change in intercanine width ($p = 0.032$), the occurrence of retainer failures ($p = 0.014$) and number of failures ($p = 0.031$). Failure was not related to treatment change in incisor irregularity, the duration of treatment, the age of the patient, gender nor to a change in intercanine width during retention. The multiple regression demonstrated that an increase in mandibular intercanine width by $\geq 3\text{mm}$ increased the odds of relapse 14.3 times (95%, CI 1.1–196.1; $p = 0.046$). Patients affected by retainer failure were 10 times (95% CI 1.6–62.8; $p = 0.014$) more likely to experience relapse. The model correctly classified 83% of cases; (Nagelkerke $R^2 = 0.253$; $p = 0.009$).

Discussion

The present research showed that a fixed retainer increases calculus accumulation. The detachment of the retainer is common, and post-treatment changes are influenced and determined by treatment changes.

The failure rate over the 2-year period of the present research was 27%, while the literature reported

a lower rate (up to 10%).^{27,28} Previous authors highlighted that after 4 years, 74% of retainers were still bonded onto the mandibular incisors.²⁹ Earlier studies compared metallic retainers with other types and revealed that multi-strand wire retainers had higher longevity when bonded from canine to canine in the mandibular arch than fibre reinforced composite retainers (mean 23.6 versus 11.5 months).³⁰ An additional study did not find a difference in the failure rates in the mandibular arch between those two fixed retainer types; however, removable thermoformed retainers demonstrated poorer stability than multistranded bonded wires.³¹ The detachment of lingual retainers during the first six months tended to be higher because the movement of teeth is greater immediately after the completion of orthodontic therapy when compared to later periods.^{32,33} During the follow-up period in the present study, it was noted that teeth which debonded were usually those which displayed relapse, but on occasion, the neighbouring teeth were affected. Patients often noticed retainer debonding after a few days, but for several, detachment remained unnoticed. Debonding was monitored upon regular check-ups, plus patients were instructed to attend as soon as a problem was noticed. However, the present study did not record how long the tooth had been unattached. In addition, there was no record of whether the entire bonded wire was replaced or simply repaired.

The frequency and reasons for retainer breakage varied; retainers are not unbreakable and do not

have 100% capacity to stabilise dental alignment.³⁴ The present study did not analyse factors related to retainer failure, but others have reported relationships that include operator experience, the dryness of the bonding field, the bonding agent, the thickness and quality of the retainer wire and occlusal trauma.³⁵ However, despite the risk, bonded wires appear to be a reliable and safe form of retention.

The crowding of mandibular incisors is the most common malocclusion in the population and, in non-extraction cases, is orthodontically resolved by an increase in arch perimeter with potentially unstable results.³⁶ The present research found more change during the retention period in the position of the incisors compared with intercanine width. The necessity of maintaining mandibular intercanine width during treatment is confirmed as post-treatment incisor irregularity is related to treatment expansion.³⁷ According to the current research, there was a linear correlation between the post-treatment change in incisor irregularity with the amount of treatment expansion and the post-treatment decrease in mandibular intercanine width. The alternative approach and quantifying the occurrence of relapse, treatment expansion in the intercanine region and retainer failure were principle factors, rather than a

post-treatment decrease in mandibular intercanine width. This could indicate that even if there is a post-treatment decrease in the intercanine width, it does not necessarily mean that there will be incisor relapse if the retainer remains intact. The multivariate analysis confirmed that treatment expansion of mandibular intercanine width emerged as the strongest predictor of relapse when all parameters were controlled. Several factors, namely growth, the gingival and periodontal tissue, the pressure from the oral soft tissues and occlusal characteristics, may be related. However, it is assumed that arch stability is increased by maintaining the original arch form.² The periodontal fibres tend to return the teeth back towards pretreatment positions. When the final occlusion is less than ideal, forces from deflecting occlusal contacts can also result in relapse. Changes in the surrounding soft tissues, and ongoing dentofacial growth can also affect tooth stability.² Several longitudinal studies have reported that minor relapse can be expected in the long term irrespective of the type of treatment or the initial malocclusion.^{38–40} Nevertheless, the amount of post-treatment increase in incisor irregularity appeared to be related to the amount of treatment correction, with a larger effect size for the upper jaw.²¹

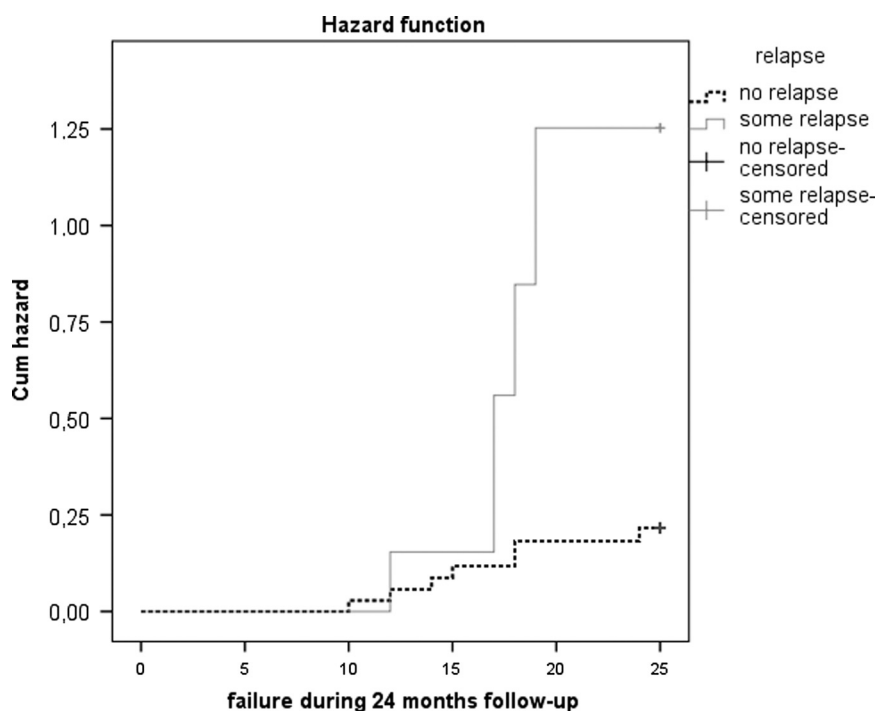


Figure 6. Hazard curves for the relationship between the time of debonding and the occurrence of relapse (Kaplan-Meier analysis).

The relationship between treatment duration and post-treatment change was not confirmed in the present study. However, a 6-year observational study implied that relapse occurred more often following short-term therapy in patients when therapy started between the ages of 9 and 12 years, and in male non-extraction patients.⁴¹ Since it is difficult to predict the patient who will experience relapse, the assurance of the outcome of treatment is achieved by maintaining a retainer in the mandibular arch for an undetermined period of time.^{29,42} Long-term follow-up and maintenance are required for bonded retainers since detachment can cause teeth to shift, plus unwanted torque expression can lead to bone loss and gingival recession.^{16,43} Unwanted and unexpected tooth movement can also occur when the orthodontic retainer wire has not broken or detached from the tooth, in a phenomenon called “Wire syndrome”.⁴⁴ This is an undesirable event, which is not a recurrence of the previous malocclusion, but heralds significant complications for the periodontium and tooth vitality.⁴⁴ Nevertheless, the present study showed that retainer failure is the strongest predictor of relapse, and the presence of a fixed retainer on the teeth reduces the likelihood.

Proper brushing, using interdental cleaning aids and self-care are also important.⁴⁵ The present research demonstrated that a fixed retainer increased calculus accumulation, although did not increase biofilm accumulation nor gingivitis. Along and beneath the bonded retaining wire, stains and calculus were often observed, and caries or white spot lesions were only exceptionally noted.^{33,46} It was noteworthy that biofilm accumulation and gingival inflammation were less frequent after 3 years of retention than at the time of debonding.⁴⁶ Short-term lingual fixed retention (3–6 months) demonstrated plaque and gingival indices and bone levels similar to those of long-term retention (>9 years); however, long-term retention presented higher calculus accumulation, increased probing depth and greater marginal recession.⁴⁷ Therefore, past literature suggests that a retention plan should be tailored for each patient by considering their attitudes towards dental hygiene.^{1,33,46,47} A 20-year follow-up study confirmed that bonded retainers are effective in maintaining tooth alignment and maintaining acceptable levels of hygiene and periodontal health.¹ Therefore, recent evidence-based literature has outlined that

orthodontic fixed retainers are not related to severe detrimental periodontal consequences and are compatible with periodontal health.^{48,49}

The present results showed that the observed changes were not related to gender. There was no significant difference between the sexes in the correction of incisal irregularity nor a change in intercanine width with therapy, as well as in the post-treatment incidence of irregularity and in the incidence of mandibular intercanine width reduction. Additionally, the incidence of retainer detachment was similar over the 2-year period. Obviously, both genders had the same level of hygiene since they presented similar biofilm and calculus accumulation along with the level of gingivitis.

The advantages of the study were the large number of subjects, the length of follow-up, and the account of gingival health, rather than just changes in the dentition. A limitation was the considerable ‘drop-out’ rate during follow-up. The reason for the considerable loss of the sample size were the restrictions due to the start of the COVID pandemic and the migration of adolescents and young adults since they changed their place of residence due to study or work. A large variation in crowding was present, but a narrow range would likely reduce the value of crowding in detecting predictors of relapse. A further limitation was the absence of a comparative control group, such as another sample of alternate patients provided with a more rigid retaining material. In addition, the evaluator was the same person who treated the patients, but intraoral conditions were assessed at different time points and plaster casts were coded to de-identify the subjects. Furthermore, plaster casts from different subjects and different time points were analysed randomly so that the chance of bias was reduced.

Conclusions

Post-treatment changes in the mandibular dental arch incorporating bonded retainers were not large, but were common. An increase in mandibular incisor irregularity during retention was mostly related to treatment-induced intercanine width expansion. A bonded retainer often detached and increased the accumulation of calculus.

Conflict of interest

The authors declare that there is no conflict of interest.

Funding

Funded by University of Rijeka grant (uniri-biomed-18-22).

Corresponding author

Biljana Dzipunova, DMD, MSc, PhD, Faculty of Dentistry, Ss. Cyril and Methodius in Skopje, Skopje, Macedonia, The former Yugoslav Republic.
Email: bibidzipun@yahoo.com, bdzipunova@stomfak.ukim.edu.mk

References

- Booth FA, Edelman JD, Proffit WR. Twenty-year follow-up of patients with permanently bonded mandibular canine-to-canine retainers. *Am J Orthod Dentofac Orthop.* 2008; 133:70–6.
- Johnston CD, Littlewood SJ. Retention in orthodontics. *Br Dent J.* 2015; 218:119–22.
- Littlewood SJ, Millett DT, Doubleday B, Bearn DR, Worthington HV. Orthodontic retention: A systematic review. *J Orthod.* 2006; 33:205–12.
- Molyneux C, Sandy JR, Ireland AJ. Orthodontic retention and the role of the general dental practitioner. *Br Dent J.* 2021; 230:753–7.
- Kingsley NW. A treatise on oral deformities as a branch of mechanical surgery. New York: D. Appleton & Co. 1880.
- Lundström AF. Malocclusion of the teeth regarded as a problem in connection with the apical base. *Am J Orthod Dentofac Orthop.* 1925; 11:591–602.
- McCauley DR. The cuspid and its function in retention. *Am J Orthod Oral Surg.* 1944; 30:196–205.
- Tweed CH. Indications for the extraction of teeth in orthodontic procedure. *Am J Orthod Oral Surg.* 1944; 30:405–28.
- Little RM, Riedel RA, Artun J. An evaluation of changes in mandibular anterior alignment from 10 to 20 years postretention. *Am J Orthod Dentofac Orthop.* 1988; 93:423–8.
- Kartal Y, Kaya B. Fixed orthodontic retainers: a review. *Turk J Orthod.* 2019; 32:110–4.
- Renkema AM, Renkema A, Bronkhorst E, Katsaros C. Long-term effectiveness of canine-to-canine bonded flexible spiral wire lingual retainers. *Am J Orthod Dentofac Orthop.* 2011; 139:614–21.
- Dahl E. Long-term experience with direct-bonded lingual retainers. *J Clin Orthod.* 1991; 25:619–30.
- Kravitz ND, Grauer D, Schumacher P, Jo YM. Memotain: A CAD/CAM nickel-titanium lingual retainer. *Am J Orthod Dentofac Orthop.* 2017; 151:812–5.
- Degirmenci Z, Ozsoy OP. Retention after fixed orthodontic treatment. *Cumhuriyet Dent J.* 2009; 12:83–90.
- Zachrisson BU. Clinical experience with direct-bonded orthodontic retainers. *Am J Orthod.* 1977; 71:440–8 [https://doi.org/10.1016/0002-9416\(77\)90247-0](https://doi.org/10.1016/0002-9416(77)90247-0).
- Zachrisson BU. Multistranded wire bonded retainers: From start to success. *Am J Orthod Dentofac Orthop.* 2015; 148:724–7.
- Diamond M. Resin fiberglass bonded retainer. *J Clin Orthod.* 1987; 21:182–3.
- Orchin JD. Permanent lingual bonded retainer. *J Clin Orthod.* 1990; 24:229–31.
- Gelin E, Seidel L, Bruwier A, Adelin Albert A, Charavet C. Innovative customized CAD/CAM nickel-titanium lingual retainer versus standard stainless-steel lingual retainer: A randomized controlled trial. *Korean J Orthod.* 2020; 50:373–82.
- Sachdeva RCL. SureSmile technology in a patient-centered orthodontic practice. *J Clin Orthod.* 2001; 35:245–53.
- Bjering R, Sandvik L, Midtbo M, Vandevska-Radunovic V. Stability of anterior tooth alignment 10 years out of retention. *J Orofac Orthop.* 2017; 78:275–83.
- Little RM, Wallen TR, Riedel RA. Stability and relapse of mandibular anterior alignment-first premolar extraction cases treated by traditional edgewise orthodontics. *Am J Orthod.* 1981; 80:349–65.
- Little RM. The irregularity index: a quantitative score of mandibular anterior alignment. *Am J Orthod.* 1975; 68:554–63.
- O'Leary TJ, Drake RB, Naylor JE. The plaque control record. *J Periodontol.* 1972; 43:38.
- Ennever J, Sturzenberger OP, Radike AW. The Calculus Surface Index method for scoring clinical calculus studies. *J Periodontol.* 1961; 32:54–7.
- Ainamo J, Bay I. Problems and proposals for recording gingivitis and plaque. *Int Dent J.* 1975; 25:229–35.
- Artun J, Marstrand PB. Clinical efficiency of two different types of direct bonded space maintainers. *ASDC J Dent Child.* 1983; 50:197–204.
- Zachrisson BU. Long-term experience with direct-bonded retainers: Update and clinical advice. *J Clin Orthod.* 2007; 41:728–37.
- Johnsson AC, Tofeldt LN, Kjelberg H. Subjective evaluation of orthodontic treatment and potential side effects of bonded lingual retainers. *Swed Dent J.* 2007; 31:35–44.
- Rose E, Jonas E. Clinical comparison of a multistranded wire and a direct-bonded polyethylene ribbon reinforced resin composite used for lingual retention. *Quintessence Int.* 2002; 33:579–83.
- Littlewood SJ, Millett DT, Doubleday B, Bearn DB, Worthington HV. Retention procedures for stabilising tooth position after treatment with orthodontic braces. *Cochrane Database Syst Rev* 2016; 2016:CD002283.
- Al-Nimri K, Al Habashneh R, Obeidat M. Gingival health and relapse tendency: a prospective study of two types of lower fixed retainers. *Aust Orthod J.* 2009; 25:142–6.
- Bearn DR. Bonded orthodontic retainers. A review. *Am J Orthod Dentofacial Orthop.* 1995; 108:207–13.
- Jedliński M, Grocholewicz K, Mazur M, Janiszewska-Olszowska J. What causes failure of fixed orthodontic retention? - systematic review and meta-analysis of clinical studies. *Head Face Med.* 2021; 17:32.
- Schneider E, Ruf S. Upper bonded retainers: Survival and failure rates. *Angle Orthod.* 2011; 81:1050–6.
- Patano A, Malcangi G, Inchingolo AD, Garofoli G, De Leonardis N, Azzollini D, et al. Mandibular crowding: diagnosis and management-a scoping review. *J Pers Med.* 2023; 13:774.
- Fleming PS, Dibiase AT, Lee RT. Arch form and dimensional changes in orthodontics. *Prog Orthod.* 2008; 9:66–73.
- Dyer KC, Vaden JL, Harris EF. Relapse revisited--again. *Am J Orthod Dentofacial Orthop.* 2012; 142:221–7.
- Freitas KM, Janson G, de Freitas MR, Pinzan A, Henriques JF, Pinzan-Vercelino CR. Influence of the quality of the finished occlusion on postretention occlusal relapse. *Am J Orthod Dentofacial Orthop.* 2007; 132:428e9–14.

40. Freitas KM, Janson G, Tompson B, de Freitas MR, Simao TM, Valarelli FP. Posttreatment and physiologic occlusal changes comparison. *Angle Orthod.* 2013; 83:239–45.
41. Lang G, Alfter G, Göz G, Lang GH. Retention and stability-taking various treatment parameters into account. *J Orofac Orthop.* 2002; 63:26–41.
42. Renkema Am, Al-Assad S, Bronkhorst E, Weindel S, Katsaros. C, Lisson JA. Effectiveness of lingual retainers bonded to the canines in preventing mandibular incisor relapse. *Am J Orthod Dentofacial Orthop.* 2008; 134: 17. e1–8.
43. Kučera J, Marek I. Unexpected complications associated with mandibular fixed retainers: a retrospective study. *Am J Orthod Dentofacial Orthop.* 2016; 149:202–11.
44. Charavet C, Vives F, Aroca S, Dridi S-M. “Wire Syndrome” following bonded orthodontic retainers: a systematic review of the literature. *Healthcare.* 2022; 10:379.
45. Lyros I, Tsolakis IA, Maroulakos MP, Fora E, Lykogeorgos T, Dalampira M, et al. Orthodontic retainers—a critical review. *Children.* 2023;10:230.
46. Artun J, Spadafora AT, Shapiro PA. A 3-year follow-up study of various types of orthodontic canine-to-canine retainers. *Eur J Orthod.* 1997; 19:501–9.
47. Pandis N, Vlahopoulos K, Madianos P, Eliades T. Long-term periodontal status of patients with mandibular lingual fixed retention. *Eur J Orthod.* 2007; 29:471–6.
48. Arn M-L, Dritsas K, Nikolaos Pandis N, Kloukos D. The effects of fixed orthodontic retainers on periodontal health: A systematic review. *Am J Orthod Dentofac Orthop.* 2020; 157: 156–64.e17.
49. Steegmans PAJ, Meursinge Reynders RA. Fixed orthodontic retainers and periodontal health. *Evid Based Dent.* 2020; 21: 146–9